Product Data Sheet

Product Name: Torsemide
Cat. No.: GC16864

Chemical Properties

Cas. No.	56211-40-6		
Chemical Name	1-[4-(3-methylanilino)pyridin-3-yl]sulfonyl-3-propan-2-ylurea		
SMILES	CC1=CC(=CC=C1)NC2=C(C=NC=C2)S(=O)(=O)NC(=O)NC(C)C		
Formula	C16H20N4O3S	M.Wt	348.42
Solubility	≥ 5.1mg/mL in DMSO	Storage	Store at -20°C
General tips	For obtaining a higher solubility , please warm the tube at 37 °C and shake it in the ultrasonic bath for a while.Stock solution can be stored below -20°C for several months.		
Shipping Condition	Evaluation sample solution : ship with blue ice All other available size: ship with RT , or blue ice upon request.		

Structure

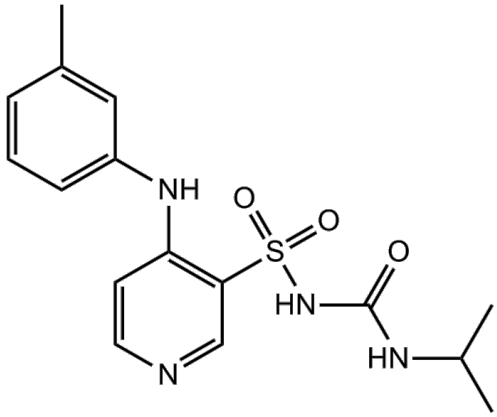

Background

Torsemide is a pyridine-sulfonyl urea type loop diuretic.Target: OthersTorasemide is a pyridine-sulfonylurea type loop diuretic mainly used in the management of edema associated with congestive heart failure. It is also used at low doses for the management of hypertension. Torsemide significantly reduced total HF readmissions (relative risk [RR]: 0.41, 95% CI: 0.28-0.61, p < 0.0001) and HF readmissions (RR: 0.53, 95% CI: 0.33-0.84, p = 0.008) as well as CV readmissions (RR: 0.77, 95% CI: 0.60-0.98, p = 0.03) in patients with "at least 1 readmission." Torsemide caused a 14%

reduction in all-cause mortality (RR: 0.86 [0.53-1.39], p = 0.54). Torsemide significantly reduces HF and CV-related hospital readmissions in systolic HF. Furthermore, torsemide is associated with a trend in reducing all-cause mortality [1]. Torsemide has several characteristics that make it suitable for treatment of advanced heart failure including longer half-life, increased potency of diuretic action, and anti-aldosterone effects. This case report details the administration of torsemide in 3 dogs with advanced heart failure and apparent furosemide resistance [2].

References:

[1]. DiNicolantonio, J.J., Should torsemide be the loop diuretic of choice in systolic heart failure Future Cardiol, 2012. 8(5): p. 707-28.
[2]. Oyama, M.A., et al., Use of the loop diuretic torsemide in three dogs with advanced heart failure. J Vet Cardiol, 2011. 13(4): p. 287-92.